

Complete Nucleus Removal for Transforaminal Lumbar Interbody Fusion (TLIF)

Transforaminal interbody fusion, or TLIF, utilizes a uniportal approach to the lumbar disc that involves removing one facet joint and accessing the disc through the intervertebral foramen (Figure 1). This approach to fusion was first discussed in the journal *Spine* in 2001, and has garnered increased acceptance as a less invasive approach to spinal fusion in the last few years, growing to an estimated 54,000 procedures globally in 2006 and 95,000 procedures by 2012. This approach to the disc avoids the potential for scar tissue and adhesion formation issues found with the descending aorta and other blood vessels in the anterior approach, and with the nerve roots in the classic posterior approach.

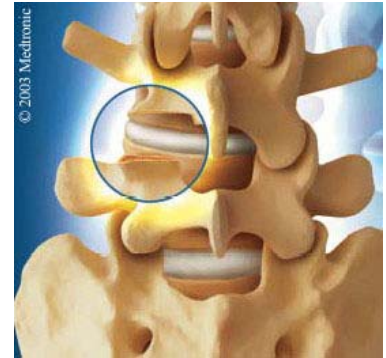


Figure 1
TLIF Approach

Disc Preparation

One of the issues with TLIF, as a minimally invasive uniportal approach, is in reaching all areas of the disc cavity in order to completely remove the nucleus tissue. Removal of the tissue contralateral (represented by the green arrow in Figure 2) to the access site (yellow arrow) using conventional instruments, i.e., the IVD rongeur, is the most challenging and is usually left in place. The problem with leaving this tissue in the disc during the fusion process is well described by Sukovich⁽¹⁾, and offers an increased likelihood of non-fusion of the vertebrae due to the decrease in the contact area between the bone graft that is inserted in the disc space and the vertebral endplates, as well as likely interference of the nucleus material with the biological process of bone formation.

Graft – Endplate Contact Area

The human lumbar spine section by Sukovich shown in Figure 2 illustrates the nucleus material typically left behind in the TLIF approach (green arrow). The yellow arrow shows the approach into the disc space. This specimen is consistent with tests performed by Javernick⁽²⁾ who reported a 69% average nucleus tissue removal from a uniportal TLIF approach. While this amount of tissue removal is greater than the 50% average removal seen by CoreSpine in their posterior approach study, it is still less than the 80% - 90% recommended by Lin⁽³⁾ for the best chance of interbody fusion. Sukovich states that most researchers agree on the necessity to have at least 50% of the endplate surface area in contact with the graft material, and that the greater the available surface area the better. The goal in fusion is to create the largest area of exposed vascular bone as possible in order to promote the osteogenic process and create a bony bridge between the vertebrae with the greatest cross-section as possible. The larger the bony bridge, the better the ultimate mechanical connection between the vertebrae and the stability of the fused tissue. Any tissue remaining in the disc serves to reduce the surface area available for fusion.

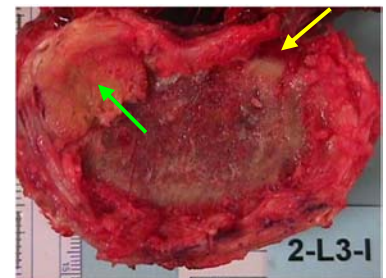


Figure 2
Remaining Material

Biology of Bone Formation

Nucleus tissue remaining in the disc during can interfere with the bone formation process not only from a mechanical perspective but also from a biological perspective. McAfee⁽⁴⁾ performed a study comparing the quality of fusion in 100 patients that had either a partial nucleus removal or a complete nucleus removal prior to anterior placement of BAK fusion cages. While McAfee did not quantify what was meant by a “complete” nucleus removal, he performed the discectomy for these patients through a larger anterior approach that allowed extensive access to the disc cavity with rongeurs and other tissue removal instruments. The patients receiving a partial nucleus removal were those for whom the only nucleus removed was as a result of reaming the holes required for the cages themselves. McAfee reported that all patients in the first group, with the complete discectomy, achieved a solid fusion and required no subsequent revision surgeries. In contrast, seven patients (14%) of the patients with a partial discectomy ended with confirmed non-fusions and required revision surgeries involving further removal of disc tissue and pedicle screw instrumented fixation. All of these patients subsequently achieved a solid fusion. McAfee attributes the successful fusions of the complete discectomy group to an increased surface area available for fusion and less avascular disc material remaining in the disc space.

Research on the effect of intervertebral disc tissue on spinal fusion in pigs by Li⁽⁵⁾ supports the results found by McAfee. Li simulated the effect of nucleus tissue remaining in a disc by placing a mixture of nucleus tissue with bone graft into Brantigan cages prior to implantation of the cages in the specimen’s disc space. In other levels, Li implanted cages with just bone graft. At 12 weeks, the levels with just bone graft had a histological fusion rate of 70%, compared to only 10% for the levels implanted with the nucleus/bone graft mixture. Li concluded that “when nucleus pulposus is mixed with the autogenous bone graft, it can delay or decrease the bone formation inside the cage, thus influencing the final fusion.” Li states that nucleus tissue is known to possess inflammatory properties and may also cause some immune reactions in the fusion environment, both of which may negatively impact the fusion process. While his model studied only fusion within the cages, it seems clear that the presence of nucleus in the disc space outside of the cage would have a similar impact on fusion in that region.

Conclusion

The presence of nucleus material remaining in the disc space can prevent a successful fusion by acting as both a physical barrier to growth of bone and as a biochemical agent delaying or preventing the osteogenic process. The challenge to complete removal of the nucleus in the uniportal TLIF approach is similar to that of the uniportal PLIF approach in that existing instrumentation is unable to adequately reach all areas of the disc. It is clear that an improved method of nucleus removal, such as the CoreSpine device, is necessary to ensure achieving the highest fusion rates possible.

References

1. Sukovich W. Progress, challenges and opportunities in disc space preparation for lumbar interbody fusion. *The Internet Journal of Spine Surgery* 1(2), 2005.
2. Javernick MA, Kuklo TR, Polly DW. Transforaminal lumbar interbody fusion: Unilateral versus bilateral disk removal - an in vivo study. *Am J Orthop* 32:344-348, 2003.
3. Lin PM. Posterior lumbar interbody fusion technique: complications and pitfalls. *Clin Orthop* 193:90-102, 1985.
4. McAfee PC, Lee GA, Fedder IL, Cunningham BW. Anterior BAK instrumentation and fusion: complete versus partial discectomy. *Clin Orthop Relat Res* 394:55-63, 2002.
5. Li H, Zou X, Laursen M, Egund N, Lind M, Bunger C. The influence of intervertebral disc tissue on the anterior spinal interbody fusion: an experimental study on pigs. *Eur Spine J* 11:476-481, 2002.